

Edward E. Wallach, M.D.
Associate Editor

Lithopedion: laparoscopic diagnosis and removal

Natalie Z. Burger, M.D.,^a Y. Elizabeth Hung, M.D., M.P.H.,^b Alexandra N. Kalof, M.D.,^c
and Peter R. Casson, M.D.^a

^a Division of Reproductive Endocrinology and Infertility, Department of Obstetrics and Gynecology, University of Vermont, Burlington, Vermont; ^b Department of Obstetrics and Gynecology, North Shore University Hospital, Manhasset, New York; and ^c Department of Pathology, University of Vermont, Burlington, Vermont

A lithopedion is an exceedingly rare obstetric phenomenon where the contents of an abdominal pregnancy calcify and become preserved. We present the case of a young woman undergoing laparoscopy for infertility during which a lithopedion was discovered. (*Fertil Steril*® 2007;87:1208–9. ©2007 by American Society for Reproductive Medicine.)

Key Words: Ectopic pregnancy, infertility, lithopedion

A 33-year-old, gravida 3, para 0, Ghanaese emigrant presented to us with a 5-year history of secondary infertility. Her three previous pregnancies had occurred in Ghana, the first two of which were aborted by dilatation and curettage (D&C), apparently without complications. In 1990, she became pregnant for the third time. During early pregnancy, she experienced general feelings of illness, with multiple episodes of syncope requiring hospitalization.

At approximately 12–14 weeks of pregnancy, she experienced heavy vaginal bleeding and received a D&C for a “missed abortion.” No abnormal findings were noted.

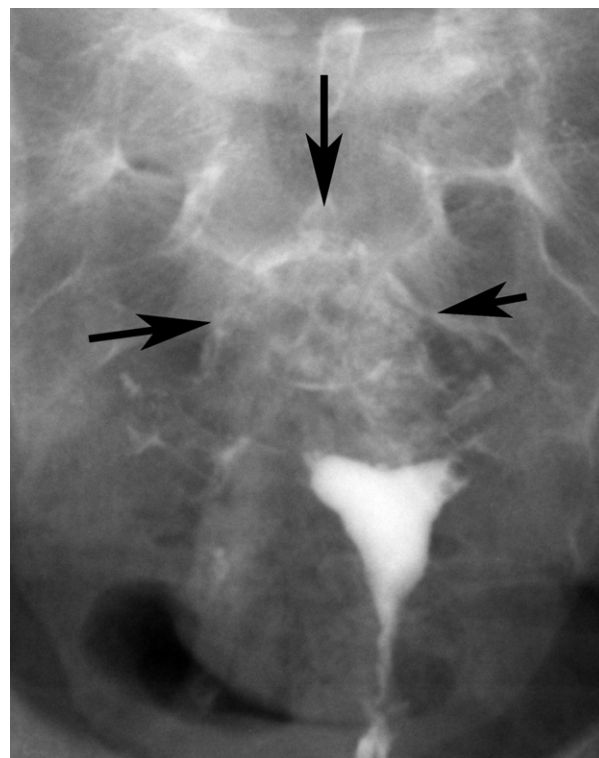
Postoperatively, the patient continued to have abdominal pain upon palpation as well as during long periods of standing and lying in the prone position. A hysterosalpingogram (HSG) performed in 1997 revealed “high-grade blockage.” A subsequent diagnostic laparoscopy confirmed bilateral tubal blockage.

When the patient presented to us in 2002, she continued to complain of episodes of the lower abdominal pain. A repeat HSG again revealed bilateral proximal tubal blockage. In retrospect, review of the HSG films revealed the outline of a fetal calvarium (Fig. 1). Because of financial considerations, the patient and her husband opted for tubal evaluation and possible repair rather than IVF. The patient was scheduled for a laparoscopy, hysteroscopy, and proximal tubal cannulation.

Received April 19, 2006; revised and accepted November 8, 2006.
There are no potential conflicts of interest of a financial or other nature.
Reprint requests: Natalie Burger, M.D., University of Vermont, Given C254, 89 Beaumont Avenue, Burlington, VT 05405 (FAX: 802-656-8771; E-mail: natalie.burger@uvm.edu).

FIGURE 1

HSG indicating the outline of a fetal calvarium.

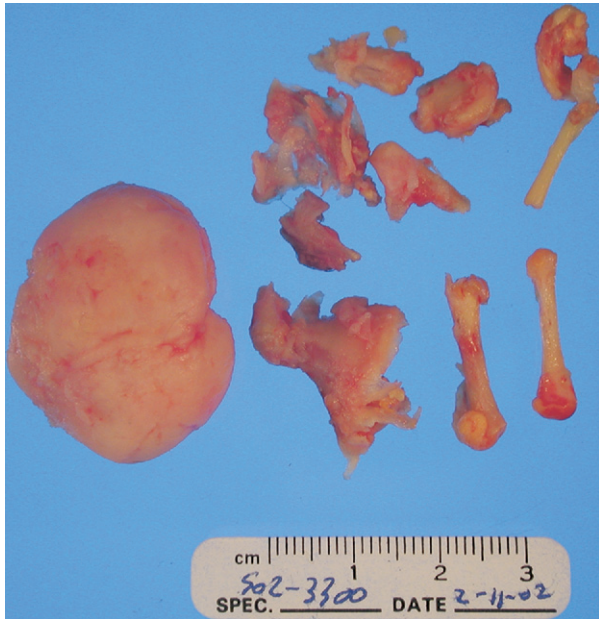


Burger. Lithopedion: diagnosis and removal. *Fertil Steril* 2007.

At the time of laparoscopy, significant pelvic adhesive disease was noted, with the distal colon adherent to the bladder and uterine fundus. Both fallopian tubes were

FIGURE 2

Surgical specimens, including an intact calvarium measuring 3 cm in diameter and multiple long bones.



Burger. Lithopedion: diagnosis and removal. *Fertil Steril* 2007.

tortuous, and the left tube was significantly dilated as well. Closer inspection revealed a foreign object near the right ovary and a firm region near the uterine fundus. Blunt dissection demonstrated a small femur and multiple other pieces of bone. Dissection of the large, firm object on the fundus demonstrated an almost intact calvarium (Fig. 2).

Laparoscopic chromopertubation confirmed tubal blockage. Hysteroscopic attempts at cannulation were unsuccessful. The patient was informed of the findings at surgery and recovered from surgery without incident.

DISCUSSION

Lithopedion, literally “stone-child” in Greek, is a rare obstetric phenomenon in which the remains of an undiagnosed extrauterine pregnancy calcify. The earliest report of such a finding was in 1582. Autopsy of a 68-year-old French woman revealed the remains of a calcified full-term fetus, the pregnancy of which had been noted 28 years earlier (1).

Approximately 300 cases have been reported in the world literature. Modern presentation of lithopedions is rare because of increased prenatal care and surveillance. However, patients presenting from areas lacking accurate diagnostic instruments may still occasionally present with such a finding. Detection of a lithopedion can be difficult, and the majority are found incidentally during surgery, radiographic imaging, or at autopsy.

Reported complications from lithopedion formation include: intestinal obstruction (2), pelvic abscess (3), cephalopelvic disproportion with future pregnancy (4), and tubal infertility (5). In our patient, we suspect that a previous pelvic infection caused scarring, which led to the ectopic pregnancy and lithopedion formation. However, it is also possible that an inflammatory reaction from the ectopic pregnancy caused the tubal damage secondarily.

Although an uncommon entity, the diagnosis of lithopedion should be entertained in infertility patients presenting from areas where modern diagnostic instruments are lacking, especially when an extrauterine mass is perceived on HSG.

REFERENCES

1. Bondeson J. The earliest known case of a lithopedion. *J R Soc Med* 1996;89:13–8.
2. Zaheer SA. Acute intestinal obstruction caused by lithopedion. *Br J Surg* 1971;58:401–2.
3. Jain T, Eckert LO. Abdominal pregnancy with lithopedion formation presenting as a pelvic abscess. *Obstet Gynecol* 2000;96(5 Pt 2):808–10.
4. Leke RJ, Nasah BT, Shasha W, Monkam G. Cephalopelvic disproportion at term involving a lithopedion: a case report. *Int J Gynaecol Obstet* 1983;21:171–4.
5. Shah-hosseini R, Evrard JR. Lithopedion: a case report. *J Reprod Med* 1987;32:131–3.